



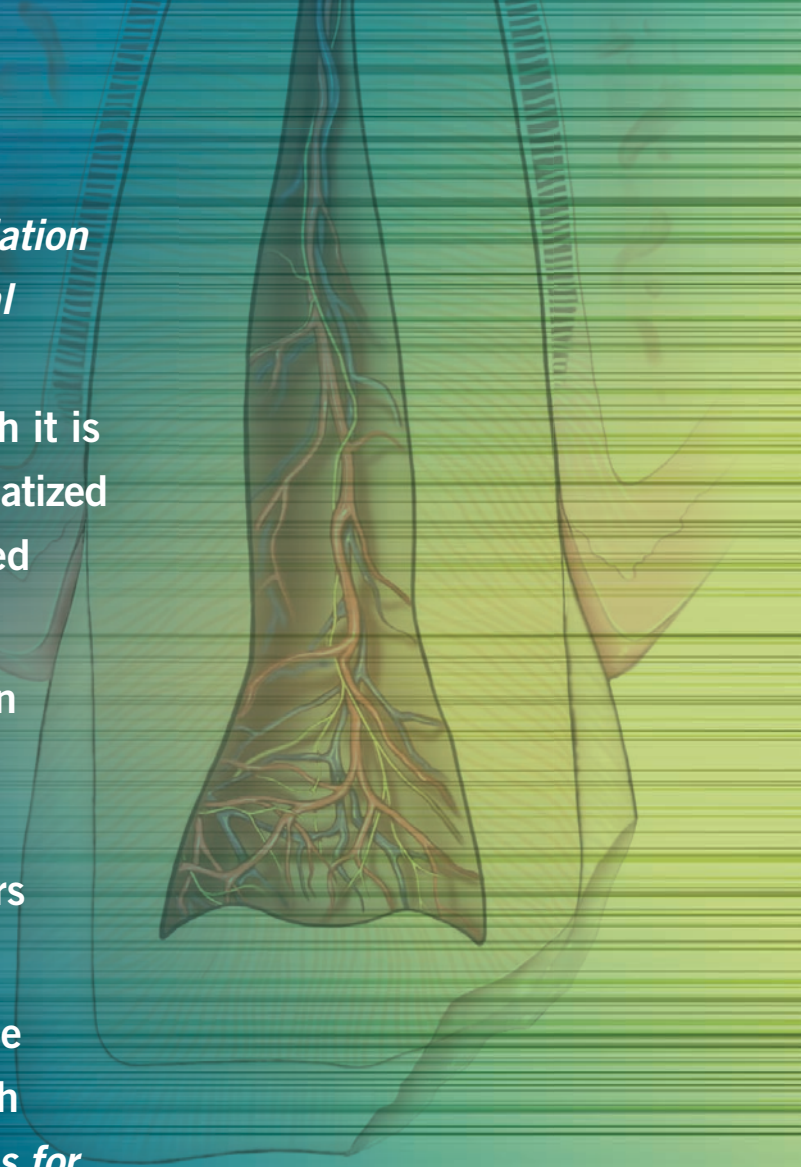
The Recommended Guidelines of the  
American Association of Endodontists for

# The Treatment of Traumatic Dental Injuries

*The Recommended Guidelines of the American Association of Endodontists for the Treatment of Traumatic Dental Injuries* are intended to aid the practitioner in the management and treatment of dental injuries. Although it is impossible to guarantee permanent retention of a traumatized tooth, timely treatment of the tooth using recommended procedures can maximize the chances for success.

The guidelines are not fixed protocols. Variations in an individual patient's health, teeth, physical condition and personal preferences are important factors in an endodontist's treatment recommendation. Practitioners cannot guarantee treatment outcomes.

The AAE gratefully acknowledges the cooperation of the International Association of Dental Traumatology, which granted the AAE permission to use the *IADT Guidelines for the Evaluation and Management of Traumatic Dental Injuries* in the development of the AAE trauma guidelines. The AAE also endorses the *IADT Guidelines*, which can be accessed at <http://www.iadt-dentaltrauma.org/for-professionals.html>.



# Table of Contents

<b>Table 1: Treatment Guidelines for Tooth Fractures and Alveolar Fractures in the Permanent Dentition .....</b>	<b>4-5</b>
<b>Table 2: Follow-Up Procedures for Fractured Permanent Teeth and Alveolar Fractures .....</b>	<b>6</b>
<b>Table 3: Treatment Guidelines for Concussion, Subluxation and Luxation of Permanent Teeth .....</b>	<b>7-9</b>
<b>Table 4: Differential Diagnosis for Concussion, Subluxation and Luxation Injuries of Permanent Teeth .....</b>	<b>10</b>
<b>Table 5: Follow-Up Procedures for Luxated Permanent Teeth.....</b>	<b>10</b>
<b>Table 6: Treatment Guidelines for Avulsed Mature Permanent Teeth with Closed Apex .....</b>	<b>11-12</b>
<b>Table 7: Treatment Guidelines for Avulsed Permanent Teeth with Open Apex .....</b>	<b>13-14</b>
<b>Table 8: Follow-Up Procedures for Avulsed Permanent Teeth with Closed &amp; Open Apices.....</b>	<b>15</b>

**Table 1: Treatment Guidelines for Tooth Fractures and Alveolar Fractures in the Permanent Dentition**

	CROWN FRACTURE		CROWN/ROOT FRACTURE	ROOT FRACTURE	ALVEOLAR FRACTURE
	UNCOMPLICATED	COMPLICATED			
DEFINITION AND DIAGNOSIS	Enamel and dentin fracture without pulp exposure.	Enamel and dentin fracture with pulp exposure.	A fracture involving enamel, dentin, and cementum with loss of tooth structure.  Crown fracture extends below gingival margin.  The pulp may or may not be exposed.	A fracture involving the root structure. It can be localized at the apical, middle or cervical third.	The bone segment containing the involved tooth/teeth is fractured and mobile.
CLINICAL ASSESMENT AND FINDINGS	Sensitivity tests and vitality tests are likely to give positive results.  Normal mobility.  Percussion test: not tender. If tenderness is observed, evaluate the tooth for possible luxation or root fracture.	Sensitivity tests and vitality tests are likely to give positive results.  Exposed pulp sensitive to stimuli.  Normal mobility.  Percussion test: not tender. If tenderness is observed, evaluate the tooth for possible luxation or root fracture	Sensitivity tests and vitality tests are likely to give positive results.  Tender to percussion.  Coronal fragment is mobile.	The coronal fragment is usually mobile and sometimes displaced.  The apical segment is usually not displaced.  Tender to percussion.  Sensitivity tests may be initially negative indicating transient pulpal damage.	Fracture lines may be located at any level, from the marginal bone to the root apex.  Mobility of the teeth may be segmental if the fracture involves more than one alveolar socket.  Occlusal interference is often present due to misalignment of the fractured alveolar segment.  Displacement of an alveolar segment.
IMAGING AND RADIOGRAPHIC ASSESSMENT AND FINDINGS	One occlusal and two periapical radiographs from mesial and distal are recommended in order to rule out displacement or the possible presence of a root fracture.  Radiograph of lip or cheek lacerations to search for tooth fragments or foreign material.	One occlusal and two periapical radiographs from mesial and distal are recommended in order to rule out displacement or the possible presence of a root fracture.  Radiograph of lip or cheek lacerations to search for tooth fragments or foreign material.	One occlusal and two periapical radiographs from mesial and distal are recommended in order to rule out displacement or the possible presence of a root fracture.  CBCT should be considered to reveal the extension and direction of the fracture.	One occlusal radiograph to determine the level of the root fracture at the apical and middle third.  Two periapical radiographs with varying horizontal angles are needed to locate the fractures in the cervical third of the root.  For a root fracture in the middle third, CBCT may rule out or confirm an oblique course of fracture involving the cervical third in the labiolingual dimension.	In addition to the three angulations and occlusal film, additional views such as a panoramic radiograph can be helpful in determining the course and position of the fracture lines.  CBCT may be useful for diagnosis of alveolar fractures, especially when they involve the palatal or both cortical plates.

Note: Pulp necrosis subsequent to trauma should be diagnosed by at least two signs or symptoms. In the noncompliant patient or one with limited access to care, with a tooth with a mature apex, a lack of response to pulp sensibility testing by 3 months is strongly indicative of pulp necrosis.

**Table 1: Treatment Guidelines for Tooth Fractures and Alveolar Fractures in the Permanent Dentition** (continued)

	CROWN FRACTURE		CROWN/ROOT FRACTURE	ROOT FRACTURE	ALVEOLAR FRACTURE
	UNCOMPLICATED	COMPLICATED			
TREATMENT	<p>If a tooth fragment is available, it can be bonded to the tooth. Otherwise perform a <u>provisional treatment</u> by covering the exposed dentin with glass ionomer or a permanent restoration using a bonding agent and composite resin.</p> <p>The <u>definitive treatment</u> for the fractured crown is restoration with accepted dental restorative materials.</p>	<p>In young patients with open apices, it is very important to preserve pulp vitality by pulp capping or partial pulpotomy in order to secure further root development.</p> <p>This treatment is also the treatment of choice in patients with closed apices.</p> <p>Calcium hydroxide compounds and MTA (white) are suitable materials for such procedures.</p> <p>If tooth fragment is available, it can be bonded to the tooth.</p> <p>Future treatment for the fractured crown may be restoration with other accepted dental restorative materials.</p>	<p>Without pulp exposure: fragment removal with or without gingivectomy and restore.</p> <p>With pulpal exposure and immature roots: Perform a partial pulpotomy to preserve pulp vitality.</p> <p>Pulp exposure with mature roots: Perform endodontic treatment then restore with a post-retained crown.</p> <p>Orthodontic or surgical extrusion of apical fragment may be indicated to expose the margins prior to permanent restoration.</p> <p>Extraction with immediate or delayed implant-retained crown restoration or a conventional bridge.</p> <p>Extraction is inevitable in crown root fractures with a severe apical extension, the extreme being a vertical fracture.</p>	<p>For root fractures where the coronal fragment has been avulsed out of the socket, please use the treatment guidelines for avulsion (Tables 6-8). Otherwise proceed as described below.</p> <p>Rinse exposed root surface with saline before repositioning.</p> <p>If displaced, reposition the coronal segment of the tooth as soon as possible.</p> <p>Check that correct position has been reached radiographically.</p> <p>Stabilize the tooth with a flexible splint for 4 weeks. If the root fracture is near the cervical area of the tooth, stabilization is beneficial for a longer period of time (up to 4 months).</p> <p>Monitor healing for at least 1 year to determine pulpal status.</p> <p>If pulp necrosis develops, then root canal treatment of the coronal tooth segment to the fracture line is indicated.</p>	<p>Reposition any displaced segment and then splint the involved teeth with a flexible splint for 4 weeks.</p> <p>Suture gingival laceration if present.</p>
PATIENT INSTRUCTIONS	Soft diet, brush teeth with a soft toothbrush after each meal, follow-up as indicated in Table 7.				

**Table 2: Follow-Up Procedures for Fractured Permanent Teeth and Alveolar Fractures**

TIME	CROWN FRACTURE		CROWN/ROOT FRACTURE		ROOT FRACTURE	ALVEOLAR FRACTURE
	UNCOMPLICATED	COMPLICATED	UNCOMPLICATED	COMPLICATED		
4 WEEKS					Splint removal*, clinical & radiographic control	Splint removal*, clinical & radiographic control
6-8 WEEKS	Clinical & radiographic control	Clinical & radiographic control	Clinical & radiographic control	Clinical & radiographic control	Clinical & radiographic control	Clinical & radiographic control
4 MONTHS					Splint removal**, clinical & radiographic control	Clinical & radiographic control
6 MONTHS					Clinical & radiographic control	Clinical & radiographic control
1 YEAR	Clinical & radiographic control	Clinical & radiographic control	Clinical & radiographic control	Clinical & radiographic control	Clinical & radiographic control	Clinical & radiographic control
YEARLY FOR 5 YEARS					Clinical & radiographic control	Clinical & radiographic control

\*Splint removal in apical third and mid-root fractures

\*\*Splint removal with a root fracture near the cervical area

**Table 3: Treatment Guidelines for Concussion, Subluxation and Luxation of Permanent Teeth**

	CONCUSSION	SUBLUXATION	EXTRUSIVE LUXATION	LATERAL LUXATION	INTRUSIVE LUXATION
DEFINITION AND DIAGNOSIS	Tooth is tender to touch and/or percussion but without displacement or abnormal mobility.	Tooth is tender to touch and/or percussion and mobile, but not displaced.	Displacement of the tooth outward or incisally.	Displacement of the tooth in any lateral direction except axially; usually associated with a fracture of the facial cortical bone.	Displacement of the tooth inward and into the alveolar bone.
CLINICAL ASSESMENT AND FINDINGS	Sensitivity and vitality tests are likely to give positive results.  Tender to percussion.	Sensitivity tests may be initially negative, indicating transient pulpal damage.  Vitality tests are likely to give positive results.  Tender to percussion.	The tooth appears elongated and is excessively mobile.  Sensitivity and vitality tests are likely to give negative results  Tender to percussion.	The tooth appears immobile or locked.  Fracture of the alveolar process may be palpable.  Sensitivity and vitality tests are likely to give negative results.  Tender to percussion.	The tooth appears partially or totally infra-occluded, immobile and locked.  Fracture of the alveolar process may be palpable.  Sensitivity and vitality tests are likely to give negative results.  Tender to percussion.
IMAGING AND RADIOGRAPHIC ASSESSMENT AND FINDINGS	Two periapical radiographs from mesial and distal to exclude displacement.  No radiographic abnormalities are expected.  CBCT should be considered if available and based on the severity of the injuries.	Two periapical radiographs from mesial and distal to exclude displacement.  No radiographic abnormalities are expected.  CBCT should be considered if available and based on the severity of the injuries.	One occlusal and two periapical radiographs from mesial and distal.  PDL space appears enlarged.  CBCT: evidence of increased PDL space and confirmation of the integrity of the socket, mainly on the sagittal and coronal planes.	One occlusal and two periapical radiographs from mesial and distal.  PDL space appears enlarged.  CBCT: evidence of increased PDL space and diagnosis of alveolar fracture, mainly on the sagittal and coronal planes.	One occlusal and two periapical radiographs from mesial and distal.  The periodontal ligament space may be absent from all or part of the root.  The cement-enamel junction is located more apically than the adjacent, non-injured teeth.  If the tooth is totally intruded, a lateral should be considered to evaluate the penetration into the nasal cavity.  CBCT: PDL space may be absent, mainly on the sagittal and coronal planes

**Table 3: Treatment Guidelines for Concussion, Subluxation and Luxation of Permanent Teeth** (continued)

	CONCUSSION	SUBLUXATION	EXTRUSIVE LUXATION	LATERAL LUXATION	INTRUSIVE LUXATION
IMMEDIATE TREATMENT	No treatment.	If needed, stabilize the tooth for 2 weeks using a flexible splint (up to 0.016" or 0.4mm).	Rinse the affected area with saline.  Reposition the tooth by gently reinserting it into the socket.  Suture gingival laceration, especially in the cervical area.  Stabilize the tooth for 2 weeks using a flexible splint (up to 0.016" or 0.4mm).	Rinse the affected area with saline.  Reposition the tooth digitally or with forceps to disengage it from its bony lock and gently reposition it into its original location.  Suture gingival laceration, especially in the cervical area.  Stabilize the tooth.  For 2 weeks using a flexible splint (up to 0.016" or 0.4mm). If displacement is extensive, splint for 4 weeks.	Teeth with incomplete root formation:  - Up to 7mm intrusion, allow for re-eruption without intervention. If no movement, initiate orthodontic repositioning within 3 weeks.  - In cases of >7mm, reposition surgically or orthodontically within 3 weeks.  Teeth with complete root formation:  - Up to 3mm intrusion and <17 years old, allow for re-eruption without intervention. If no movement after 2–3 weeks, reposition surgically or orthodontically before ankylosis develops.  - Between 3-7mm intrusion, reposition surgically or orthodontically within 3 weeks.  In cases of >7mm, reposition surgically. Splint for 2 weeks using a flexible splint. If displacement is extensive, splint for 4 weeks.  - Suture gingival laceration, especially in the cervical area.



**Table 3: Treatment Guidelines for Concussion, Subluxation and Luxation of Permanent Teeth** (continued)

	CONCUSSION	SUBLUXATION	EXTRUSIVE LUXATION	LATERAL LUXATION	INTRUSIVE LUXATION
ENDODONTIC TREATMENT AND CONSIDERATIONS	Monitor pulpal response until a definitive pulpal diagnosis can be made.	Monitor pulpal response until a definitive pulpal diagnosis can be made.	Teeth with incomplete root formation: - Monitor closely for pulp vitality. - If the pulp becomes necrotic, pulp revascularization therapy or apexification should be considered.  Teeth with complete root formation: Pulp necrosis is a common complication. If diagnosed, root canal treatment is indicated.	Teeth with incomplete root formation: - Monitor closely for pulp vitality. - If the pulp becomes necrotic, pulp revascularization therapy or apexification should be considered.  Teeth with complete root formation: Pulp necrosis is a common complication. If diagnosed, root canal treatment is indicated.	Teeth with incomplete root formation: - Monitor closely for pulp vitality. - If the pulp becomes necrotic, pulp revascularization therapy or apexification should be considered.  Teeth with complete root formation: - The pulp will likely become necrotic and root canal therapy should be initiated 2 weeks after the injury. - After cleaning and disinfection, a temporary dressing with calcium hydroxide is recommended for up to 4 weeks.
PATIENT INSTRUCTIONS	Soft food for 1 week. Maintain good oral hygiene. 0.12% chlorhexidine rinses bid for 2 weeks.	Soft food for 1 week. Maintain good oral hygiene. 0.12% chlorhexidine rinses bid for 2 weeks	Soft food for 1 week. Maintain good oral hygiene. 0.12% chlorhexidine rinses bid for 2 weeks.	Soft food for 1 week. Maintain good oral hygiene. 0.12% chlorhexidine rinses bid for 2 weeks.	Soft food for 1 week. Maintain good oral hygiene. 0.12% chlorhexidine rinses bid for 2 weeks.

**Table 4: Differential Diagnosis for Concussion, Subluxation and Luxation Injuries of Permanent Teeth**

	CONCUSSION	SUBLUXATION	LUXATION EXTRUSIVE LATERAL INTRUSIVE
PERCUSSION	YES	YES	YES
MOBILITY	NO	YES	YES
DISPLACEMENT	NO	NO	YES

**Table 5: Follow-up Procedures for Luxated Permanent Teeth**

TIME	CONCUSSION/SUBLUXATION	EXTRUSION	LATERAL LUXATION	INTRUSION
2 WEEKS	Splint removal (if applied for subluxation) Clinical and radiographic examination	Splint removal Clinical and radiographic examination	Clinical and radiographic examination	Clinical and radiographic examination
4 WEEKS	Clinical and radiographic examination	Clinical and radiographic examination	Splint removal Clinical and radiographic examination	Splint removal Clinical and radiographic examination
6-8 WEEKS	Clinical and radiographic examination	Clinical and radiographic examination	Clinical and radiographic examination	Clinical and radiographic examination
6 MONTHS	Clinical and radiographic examination	Clinical and radiographic examination	Clinical and radiographic examination	Clinical and radiographic examination
1 YEAR	Clinical and radiographic examination	Clinical and radiographic examination	Clinical and radiographic examination	Clinical and radiographic examination
2-5 YEARS	Yearly up to 5 years	Yearly up to 5 years	Yearly up to 5 years	Yearly up to 5 years

**Table 6: Treatment Guidelines for Avulsed Mature Permanent Teeth with Closed Apex**

DIAGNOSIS & CLINICAL SITUATION	TOOTH HAS ALREADY BEEN REPLANTED	TOOTH HAS BEEN KEPT IN PHYSIOLOGIC STORAGE MEDIUM OR OSMOLALITY BALANCED MEDIUM (HBSS, SALINE, AND MILK) AND/OR STORED DRY FOR UP TO 60 MINUTES	EXTRA-ORAL DRY TIME > 60 MINUTES
<b>IMMEDIATE TREATMENT</b>	<p>Leave tooth in place.</p> <p>Clean affected area with water, saline or 0.12% chlorhexidine.</p> <p>Suture gingival laceration, especially in the cervical area.</p> <p>Verify normal position of the replanted tooth radiographically.</p> <p>Apply a flexible splint for 1-2 weeks (up to 0.016” or 0.4mm).</p> <p>If an intracanal corticosteroid medication is chosen to be used as an anti-inflammatory, anticlastic medicament, it should be placed immediately or shortly following replantation and left for at least 2 weeks.**</p>	<p>Hold the tooth by the crown and clean the root surface and apical foramen with saline.</p> <p>Administer local anesthesia.</p> <p>Irrigate the socket with saline.</p> <p>Examine the socket for possible fracture and reposition if necessary.</p> <p>Replant the tooth slowly with slight digital pressure.</p> <p>Suture gingival laceration, especially in the cervical area.</p> <p>Verify normal position of the replanted tooth radiographically.</p> <p>Apply a flexible splint for 1-2 weeks (up to 0.016” or 0.4mm).</p> <p>If an intracanal corticosteroid medication is chosen to be used as an anti-inflammatory, anticlastic medicament, it should be placed immediately or shortly following replantation and left for at least 2 weeks.**</p>	<p>Carefully remove necrotic tissue attached to the root using gauze.</p> <p>To slow down osseous replacement of the tooth, treatment of the root surface with fluoride prior to replantation has been suggested (2% sodium fluoride solution for 20 min) but it should not be seen as an absolute recommendation.</p> <p>Administer local anesthesia.</p> <p>Irrigate the socket with saline.</p> <p>Examine the socket for possible fracture and reposition if necessary.</p> <p>Root canal treatment can be carried out prior to replantation or later.</p> <p>If an intracanal corticosteroid medication is chosen to be used as an anti-inflammatory, anticlastic medicament, it should be placed immediately or shortly following replantation and left for at least 2 weeks.**</p> <p>Replant the tooth slowly with slight digital pressure.</p> <p>Suture gingival laceration, especially in the cervical area.</p> <p>Verify normal position of the replanted tooth radiographically.</p> <p>Apply a flexible splint for 1-2 weeks (up to 0.016” or 0.4mm).</p>
<b>IMAGING AND RADIOGRAPHIC ASSESSMENT AND FINDINGS</b>	<p>Two periapical radiographs from mesial and distal.</p> <p>CBCT should be considered to confirm the reposition of the tooth and rule out alveolar bone fracture(s).</p>		
<b>ENDODONTIC TREATMENT AND CONSIDERATIONS</b>	<p>If endodontic treatment was not initiated immediately after replantation (read above), root canal treatment should be initiated 7-10 days after replantation and before splint removal.</p> <p>Calcium hydroxide is recommended as an intracanal medication for up to 4 weeks followed by root canal filling.</p>		

**Table 6: Treatment Guidelines for Avulsed Mature Permanent Teeth with Closed Apex** (continued)

DIAGNOSIS & CLINICAL SITUATION	TOOTH HAS ALREADY BEEN REPLANTED	TOOTH HAS BEEN KEPT IN PHYSIOLOGIC STORAGE MEDIUM OR OSMOLALITY BALANCED MEDIUM (HBSS, SALINE, AND MILK) AND/OR STORED DRY FOR UP TO 60 MINUTES	EXTRA-ORAL DRY TIME > 60 MINUTES
ANTIBIOTICS	Prescribe systemic antibiotics: In patients <12 years old: amoxicillin for 7 days at appropriate dose for patient's age and weight. In patients >12 years old: doxycycline for 7 days, at appropriate dose for patient's age and weight. If the avulsed tooth has been in contact with soil, and if tetanus coverage is uncertain, refer to physician for a tetanus booster.		
PATIENT INSTRUCTIONS	Avoid participation in contact sports for at least 2 weeks. Soft diet for 2 weeks. Brush teeth with a soft toothbrush after each meal. Use a 0.12% chlorhexidine mouth rinse twice a day. Use a mouthguard for protection during contact sports.		
FOLLOW-UP	Splint removal and clinical and radiographic examination after 2 weeks.  Clinical and radiographic examination at 4 weeks, 3 months, 6 months, 1 year and then yearly thereafter for 5 years.	Splint removal and clinical and radiographic examination after 2 weeks.  Clinical and radiographic examination at 4 weeks, 3 months, 6 months, 1 year and then yearly thereafter for 5 years.	Splint removal and clinical and radiographic examination after 2 weeks.  Clinical and radiographic examination at 4 weeks, 3 months, 6 months, 1 year and then yearly thereafter for 5 years.  Ankylosis is unavoidable after delayed replantation and must be taken into consideration.  In children and adolescents, ankylosis is frequently associated with infraposition. Careful follow-up is required and good communication is necessary to ensure the patient and guardian of this likely outcome.  Decoronation may be necessary when infraposition (>1mm) is seen,

**Table 7: Treatment Guidelines for Avulsed Permanent Teeth with Open Apex**

DIAGNOSIS & CLINICAL SITUATION	TOOTH HAS ALREADY BEEN REPLANTED	TOOTH HAS BEEN KEPT IN PHYSIOLOGIC STORAGE MEDIUM OR OSMOLALITY BALANCED MEDIUM (HBSS, SALINE, AND MILK) AND/OR STORED DRY FOR UP TO 60 MINUTES	EXTRA-ORAL DRY TIME > 60 MINUTES
<b>IMMEDIATE TREATMENT</b>	<p>Leave tooth in place.</p> <p>Clean affected area with water, saline or 0.12% chlorhexidine.</p> <p>Suture gingival laceration, especially in the cervical area.</p> <p>Verify normal position of the replanted tooth radiographically.</p> <p>Apply a flexible splint for 2 weeks (up to 0.016" or 0.4mm).</p>	<p>If contaminated, clean the root surface and apical foramen with a stream of saline. Do not handle the root.</p> <p>Soak the tooth in doxycycline or minocycline (1 mg per 20 ml of saline) for 5 minutes (if available).</p> <p>Administer local anesthesia.</p> <p>Irrigate the socket with saline.</p> <p>Examine the socket for possible fracture and reposition if necessary.</p> <p>Replant the tooth slowly with slight digital pressure.</p> <p>Suture gingival laceration, especially in the cervical area.</p> <p>Verify normal position of the replanted tooth radiographically.</p> <p>Apply a flexible splint for 2 weeks (up to 0.016" or 0.4mm).</p>	<p>Carefully remove necrotic tissue attached to the root using gauze.</p> <p>Administer local anesthesia.</p> <p>Irrigate the socket with saline.</p> <p>Examine the socket for possible fracture and reposition if necessary.</p> <p>Preferably, root canal treatment should be carried out prior to replantation</p> <p>Replant the tooth slowly with slight digital pressure.</p> <p>Suture gingival laceration, especially in the cervical area.</p> <p>Verify normal position of the replanted tooth radiographically.</p> <p>Apply a flexible splint for 4 weeks (up to 0.016" or 0.4mm).</p>
<b>IMAGING AND RADIOGRAPHIC ASSESSMENT AND FINDINGS</b>	<p>Two periapical radiographs from mesial and distal.</p> <p>CBCT should be considered to confirm the reposition of the tooth and rule out alveolar bone fractures.</p>		
<b>ENDODONTIC TREATMENT AND CONSIDERATIONS</b>	<p>The goal for replanting developing and immature teeth in children is to allow for possible revascularization of the pulp space.</p> <p>For very immature teeth, root canal treatment should be avoided unless there is clinical or radiographic evidence of pulp necrosis.</p> <p>If pulp necrosis is diagnosed, pulp revascularization or root canal treatment (apexification) may be recommended.</p>		<p>The root canal was completed prior to replantation.</p> <p>Delayed replantation has a poor long-term prognosis. The periodontal ligament will be necrotic and not expected to heal. The goal in delayed replantation is to temporarily restore the tooth to the dentition for aesthetic, functional and psychological reasons and to maintain alveolar contour. The eventual outcome will be ankylosis and resorption of the root.</p> <p>Decoronation may be necessary when infraposition (&gt;1mm) is seen.</p>

**Table 7: Treatment Guidelines for Avulsed Permanent Teeth with Open Apex** (continued)

DIAGNOSIS & CLINICAL SITUATION	TOOTH HAS ALREADY BEEN REPLANTED	TOOTH HAS BEEN KEPT IN PHYSIOLOGIC STORAGE MEDIUM OR OSMOLALITY BALANCED MEDIUM (HBSS, SALINE, AND MILK) AND/OR STORED DRY FOR UP TO 60 MINUTES	EXTRA-ORAL DRY TIME > 60 MINUTES
ANTIBIOTICS	Prescribe systemic antibiotics: In patients <12 years old: amoxicillin for 7 days at appropriate dose for patient's age and weight. In patients >12 years old: doxicycline for 7 days, at appropriate dose for patient's age and weight. If the avulsed tooth has been in contact with soil, and if tetanus coverage is uncertain, refer to physician for a tetanus booster.		
PATIENT INSTRUCTIONS	Avoid participation in contact sports for at least 2 weeks. Soft diet for 2 weeks. Brush teeth with a soft toothbrush after each meal. Use a 0.12% chlorhexidine mouth rinse twice a day. Use a mouthguard for protection during contact sports.		
FOLLOW-UP	Splint removal and clinical and radiographic examination after 2 weeks. Clinical and radiographic examination at 4 weeks, 3 months, 6 months, 1 year and then yearly thereafter for 5 years.	Splint removal and clinical and radiographic examination after 2 weeks. Weight and height measurements as a baseline for growth. This may become critical to determine the time of decoronation, if needed. Clinical and radiographic examination at 4 weeks, 3 months, 6 months, 1 year and then yearly thereafter for 5 years.	Splint removal and clinical and radiographic examination after 4 weeks. Clinical and radiographic examination at 2 and 4 weeks, 3 months, 6 months, 1 year and then yearly thereafter for 5 years. Ankylosis is unavoidable after delayed replantation and must be taken into consideration. In children and adolescents ankylosis is frequently associated with infraposition. Careful follow-up is required and good communication is necessary to ensure the patient and guardian of this likely outcome. Growth follow-up: weight and height measurements. Decoronation may be necessary when infraposition (>1mm) is seen.

**Table 8: Follow-Up Procedures for Avulsed Permanent Teeth with Closed & Open Apices**

TIME	CLOSED APEX/EXTRAORAL DRY TIME <60 MINUTES	CLOSED APEX/EXTRAORAL DRY TIME >60 MINUTES	OPEN APEX/REGARDLESS OF EXTRAORAL DRY TIME
7-10 DAYS	Root canal treatment & calcium hydroxide for up to 4 weeks. Weight and height measurements as a baseline for growth. This may become critical to determine the time of decoronation, if needed.		No root canal treatment unless clinical or radiographic signs of pulp necrosis are evident. Weight and height measurements as a baseline for growth. This may become critical to determine the time of decoronation, if needed.
2 WEEKS	Splint removal.		Splint removal/clinical & radiographic examination.
4 WEEKS	Clinical & radiographic examination. Root canal filling.		Clinical & radiographic examination
3 MONTHS	Clinical & radiographic examination. Growth follow-up: weight and height measurements.		
6 MONTHS	Clinical & radiographic control. Growth follow-up: weight and height measurements.		
1 YEAR	Clinical & radiographic control. Growth follow-up: weight and height measurements.		
YEARLY	Clinical & radiographic control. Growth follow-up: weight and height measurements.		



## AMERICAN ASSOCIATION OF ENDODONTISTS

211 E. Chicago Ave., Suite 1100, Chicago, IL 60611-2691

Phone: 800/872-3636 (U.S., Canada, Mexico) or 312/266-7255

Fax: 866/451-9020 (U.S., Canada, Mexico) or 312/266-9867

Email: [info@aae.org](mailto:info@aae.org) Website: [www.aae.org](http://www.aae.org)

 [www.facebook.com/endodontists](http://www.facebook.com/endodontists)

 [@aaenews](https://twitter.com/aaenews) | [@savingyourteeth](https://twitter.com/savingyourteeth)

 [www.youtube.com/rootcanalspecialists](http://www.youtube.com/rootcanalspecialists)